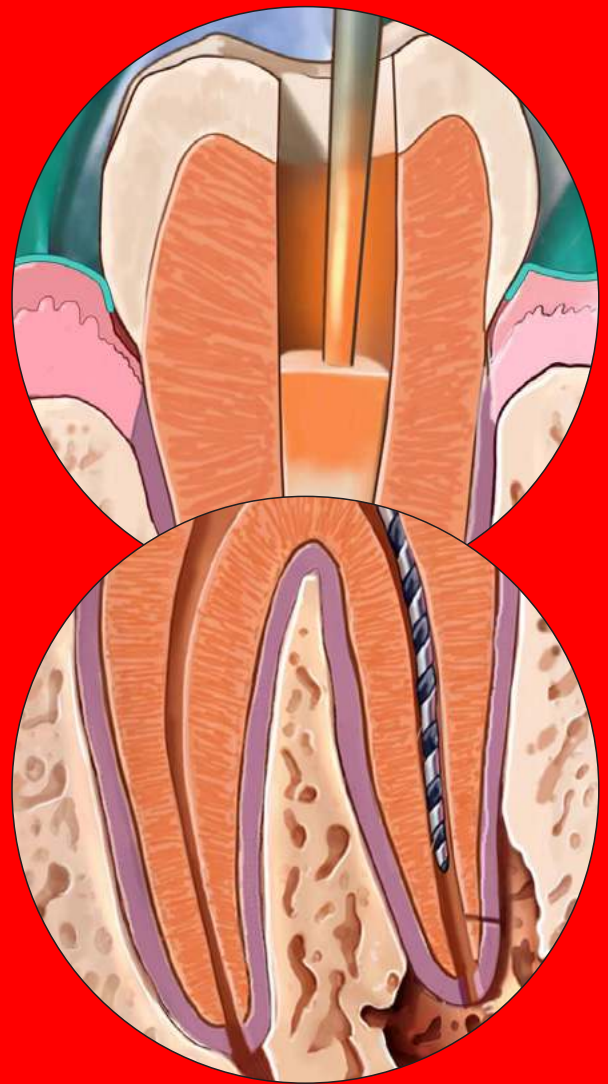



Canal Preparation and Obturation: An Updated View of the Two Pillars of Nonsurgical Endodontics



Colleagues for Excellence

Published for the dental professional community by the



american association of
endodontists

ENDODONTICS: Colleagues for Excellence

The ultimate goal of endodontic treatment is the long-term retention in function of teeth with pulpal or periapical pathosis. Depending on the diagnosis, this therapy typically involves the preparation and obturation of all root canals. Both steps are critical to an optimal long-term outcome. This publication is intended to update clinicians on the current understanding of best practices in the two pillars of nonsurgical endodontics, canal preparation and obturation, and to highlight strategies for decision making in both uncomplicated and more difficult endodontic cases.

Prior to initiating therapy, a clinician must establish a diagnosis, take a thorough patient history and conduct clinical tests. Recently, judicious use of cone beam computed tomography (CBCT) has augmented the clinically available imaging modalities. Verifying the mental image of canal anatomy goes a long way to promote success in canal preparation. For example, a missed canal frequently is associated with endodontic failures (1). As most maxillary molars have two canals in the mesiobuccal root, case referral to an endodontist for microscope-supported treatment should be considered. Endodontists are increasingly using CBCT and the operating microscope to diagnose and treat anatomically challenging teeth, such as those with unusual root anatomies, congenital variants or iatrogenic alteration. The endodontic specialist, using appropriate strategies, can achieve good outcomes even in cases with significant challenges (Figure 1).

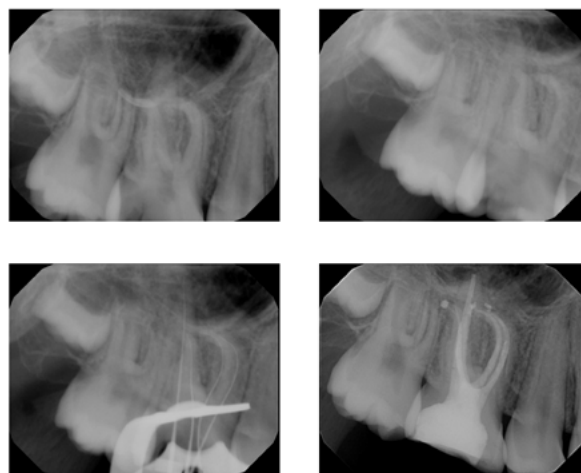


Fig. 1. Root canal treatment of tooth #3 diagnosed with pulp necrosis and acute apical periodontitis. The mesiobuccal root has a significant curve and two canals with separate apical foramina. (Case courtesy of Dr. Jeffrey Kawilarang.)

Preparation of the Endodontic Space

The goal of canal preparation is to provide adequate access for disinfecting solutions without making major preparation errors such as perforations, canal transportations, instrument fractures or unnecessary removal of tooth structure. The introduction of nickel-titanium (NiTi) instruments to endodontics almost two decades ago (2) has resulted in dramatic improvements for successful canal preparation for generalists and specialists. Today there are more than 50 canal preparation systems; however, not every instrument system is suitable for every clinician and not all cases lend themselves to rotary preparation. Several key factors have added versatility in this regard. For example, the emergence of special designs such as orifice shapers and mechanized glide path files. Another recent development is the application of heat treatment to nickel titanium alloy, both before and after the file is manufactured. Deeper knowledge of metallurgical properties is desirable for clinicians who want to capitalize on these new alloys. Finally more recent strategies such as minimally invasive endodontics have emerged (3).

Basic Nickel Titanium Metallurgy

What makes NiTi so special? It is highly resistant to corrosion and, more importantly, it is highly elastic and fracture-resistant. NiTi exists reversibly in two conformations, martensite and austenite, depending on external tension and ambient temperature. While steel allows 3% elastic deformation, NiTi in the austenitic form can withstand deformations of up to 7% without permanent damage or plastic deformation (4). Knowing this is critical for rotary endodontic instruments for two reasons. First, during preparation of curved canals, forces between the canal wall and abrading instruments are smaller with more elastic instruments, hence less preparation errors are likely to occur. Second, rotation in curved canals will bend instruments once per rotation, which ultimately will lead to work hardening and brittle fracture, also known as cyclic fatigue. Steel can withstand up to 20 complete bending cycles while NiTi can endure up to 1,000 cycles (4).

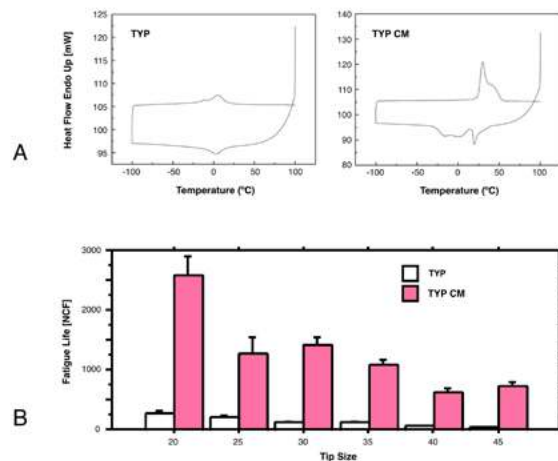


Fig. 2. Behavior of controlled-memory nickel-titanium rotaries compared to standard instruments. Shown is data from Typhoon™. Differential scanning calorimetry shows the transition between austenite and martensite at about 5°C for standard NiTi and at about 25°C for controlled-memory (CM) alloy (A). At room temperature, this results in a drastically increased fatigue lifespan (B). (Image A modified and reprinted with permission from Shen et al. *J Endod* 2011;37:1566-71.)

Canal Preparation and Obturation: An Updated View of the Two Pillars of Nonsurgical Endodontics

Recently manufacturers have learned to produce NiTi instruments that are in the martensitic state and even more flexible than previous files. Figure 2 shows how instrument conditions (austenite vs. martensite) are determined in the testing laboratory, using prescribed heating and cooling cycles (5). Heat-treated files with high martensite content typically do not have a silver metallic shade but are colored due to an oxide layer, such as gold or blue. It is important to note that CM files frequently deform; however, with a delicate touch, cutting is adequate and often even superior to conventional NiTi instruments (6). It is imperative for clinicians to retrain themselves prior to using these new instruments to avoid excessive deformation and subsequent instrument fracture.

Preparation Strategies

Experimental and clinical evidence suggests that the use of NiTi instruments combined with rotary movement results in improved preparation quality. Specifically, the incidence of gross preparation errors is greatly reduced (7). Canals with wide oval or ribbon-shaped cross-sections present difficulties for rotary instruments and strategies such as circumferential filing and ultrasonics should be used in those canals. Studies found that oscillating instruments recommended for these canal types did not perform as well (8), particularly in curved canals. Specific instruments developed to address these challenges include the Self-Adjusting File (SAF) System (ReDentNOVA, Raana, Israel), TRUShape® (Dentsply Sirona, Tulsa, OK) and XP Endo® (Brasseler, Savannah, GA). However, there is no direct clinical evidence that these instruments lead to better outcomes.

Canal transportation with contemporary NiTi rotaries, measured as undesirable changes of the canal center seen in cross-sections of natural teeth, is usually very small. This indicates that canal walls are not excessively thinned and apical canal paths are only minimally straightened (Fig. 1), even when preparing curved root canals. While preparation usually removes dentin somewhat preferentially towards the outside of the curvature (9), current NiTi instruments, including reciprocating files, can enlarge the canal path safely while minimizing procedural errors.

Almost all current rotaries are non-landed, meaning they have sharp cutting edges, and they can be used in lateral action towards a specific point on the perimeter. This “brushing” action allows the clinician to actively change canal paths away from the furcation in the coronal and middle thirds of the root canal (10) but may create apical canal straightening when taken beyond the apical constriction. Circumferential engagement of canal walls by active instruments may lead to a threading-in effect but contemporary rotaries are designed with variable pitch and helical angle to counteract this tendency.

An important design element for all contemporary rotaries is a passive, non-cutting tip that guides the cutting planes to allow for more evenly distributed dentin removal. Rotaries with cutting, active tips such as dedicated retreatment files should be used with caution to avoid preparation errors.

NiTi Instrument Usage

As a general rule, flexible instruments are not very resistant to torsional load but are resistant to cyclic fatigue. Conversely, more rigid files can withstand more torque but are susceptible to fatigue. The greater the amount and the more peripheral the distribution of metal in the cross section, the stiffer the file (11). Therefore, a file with greater taper and larger diameter is more susceptible to fatigue failure; moreover, a canal curvature that is more coronal is more vulnerable to file fracture.

Instrument handling has been shown to be associated with file fracture. For example, a lower rotational speed (~250 rpm) results in delayed build-up of fatigue (12) and reduced incidence of taper lock (13). Material imperfections such as microfractures and milling marks are believed to act as fracture initiation sites (14). Such surface imperfections after manufacturing can be removed by electropolishing but it is unclear if this process extends fatigue life (15).

Manufacturers’ recommendations stress that rotaries should be advanced with very light pressure; however, the recommendations differ with regard to the way the instruments are moved. A typical recommendation is to move the instrument into the canal gently in an in-and-out motion for three to four cycles, directed away from the furcation, then withdraw to clean the flutes.

It is difficult to determine exactly the apically exerted force in the clinical setting; experiments have suggested that forces start at about 1 Newton (N) and range up to 5 N (16). Precise torque limits have been discussed as a means to reduce failure. Most clinicians use torque-controlled motors, which are based on presetting a maximum current for a DC electric motor.

In order to reduce friction, manufacturers often recommend the use of gel-based lubricants in dentin; however, such lubricants have not been shown to be beneficial and actually did increase torque for radial-landed ProFile® instruments (17). Therefore, it is recommended to flood the canal system with sodium hypochlorite (NaOCl) during the use of rotaries. The best way to do this is to create an access cavity that can act as a reservoir (Figure 3).

ENDODONTICS: Colleagues for Excellence

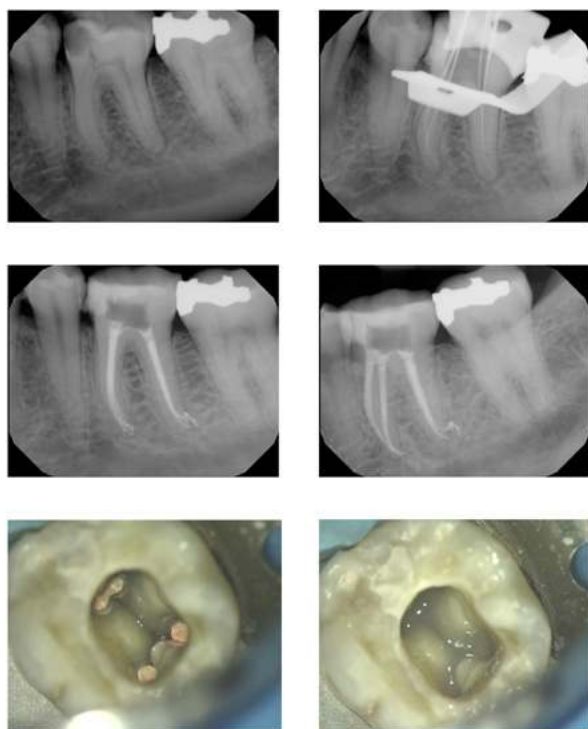


Fig. 3. Root canal treatment of tooth #19 with four canals diagnosed with irreversible pulpitis and acute apical periodontitis. A second canal in the distal root of a mandibular molar is not infrequent. Note multiple apical foramina in both the mesial and the distal apices. Prior to temporization the orifices were protected with a barrier of light-curing glass ionomer. (Case courtesy of Dr. Paymon Bahrami.)

There are several concerns about reusing NiTi instruments. The effectiveness of disinfection procedures is not clear. It has been shown that protein particles cannot completely be removed from machined nickel-titanium surfaces (18). Moreover, it is clear that with additional usage, the chance for instrument fracture increases. Current recommendations advise that clinicians are judicious when reusing rotary instruments as there is no conclusive evidence of disease transmission occurring.

Recently, the term minimally invasive endodontics has been used to describe smaller-than-usual apical sizes and perhaps more importantly, an understanding that the long-term success of root canal-treated teeth will improve by retaining as much dentin structure as feasible (3). The thought process for this was the finding that most root-canal treated teeth survive 10 years and longer (19). In studies, the reasons cited for the extraction vary but in many cases teeth are either fractured or non-restorable for other reasons (20, 21). In consequence, a smaller coronal dimension of rotaries is considered while maintaining apical sizes to support antimicrobial efficacy. There currently is no direct clinical evidence to support this strategy but it is clear that root fractures pose problems in the long-term outcomes of our patients. Another recent development is the emergence of certain specialized rotaries, such as dedicated orifice shapers and so-called glide path files. The orifice shapers have larger tapers, such as .08, which means that they are not flexible and can overprepare at the canal orifice level. Glide path files, for example PathFiles® and ProGlider® (Dentsply Sirona), are delicate instruments and may fracture when used incorrectly. It is recommended to use a small K-file (size #10) before any rotary instrumentation and to use a delicate touch.

Clinical Results

While results from *in vitro* studies on rotary systems are abundant, clinical studies on these instruments are sparse. Comparing NiTi and stainless steel K-files, Pettiette et al. (7) found less canal transportation and fewer gross preparation errors such as strip perforations. Subsequently, using radiographic evaluation of the same patient group, they demonstrated better healing in the NiTi group (22). An earlier outcome study with three rotary preparation paradigms did not show any difference between the three systems with an overall favorable outcome rate of about 87% (23).

The most consistent clinical results are obtained when the manufacturer's directions are followed. While these vary by instrument, a set of common rules apply to root canal preparation. Root canal systems are best prepared in the following sequence:

- Analysis of the specific anatomy of the case
- Canal scouting
- Coronal modifications
- Negotiation to patency
- Determination of working length
- Glide path preparation
- Root canal shaping to desired size
- Gauging the foramen, apical adjustment

Obturation of the Endodontic Space

A well-shaped and cleaned canal system should create the conditions for intact periapical tissues. On the other hand, this root canal system is inaccessible to the body's immune system and therefore it cannot combat coronal leakage. Accordingly, best practices dictate that root canals should be filled as completely as possible in order to prevent ingress of nutrients or oral microorganism. None of the established techniques for root canal filling provides a definitive coronal, lateral and apical seal (24).

Basic Strategies in Root Canal Obturation

Ideally, root canal fillings should seal all foramina leading to the periodontium, be without voids, adapt to the instrumented canal walls, and end at working length. There are various acceptable materials and techniques to obturate root canal systems including:

- sealer (cement/paste/resin) only
- sealer and a single cone of a stiff or flexible core material
- sealer coating combined with cold compaction of core materials
- sealer coating combined with warm compaction of core materials
- sealer coating combined with carrier-based core materials

Several of these techniques have shown comparable success rates regarding apical bone fill or healing of periradicular lesions, so a clinician may choose from a variety of techniques and approaches that works best for him or her. Existing research directs clinicians towards preparation and disinfection of the root canal as the single most important factor in the treatment of endodontic pathosis, and no particular sealing technique can claim superior healing success (25).

Current Developments in Root Canal Obturation Materials

After the introduction of MTA (mineral trioxide aggregate) as a material for perforation repair and apical surgery more than two decades ago, materials with similar bioactive properties now are available as root canal sealers. Bioceramic root canal cement (BC Sealer™, Brasseler) has clinically acceptable radiopacity and flow (26). Moreover, it is well-tolerated in cell culture experiments (27). However, there is no clinical evidence that using this cement leads to better outcomes. In fact, most research has indicated the type of cement used has comparatively little impact (28).

In contemporary practice, heat generators are used to plasticize gutta-percha. Additionally, cordless heating devices are available. Another recent addition is a carrier-based material, Guttacore® (Dentsply Sirona), which uses modified gutta-percha materials instead of plastic as its base. Early data indicate that obturation with this new material is similar to warm vertical compaction or lateral compaction (29).

Practical Aspects of Obturation

The main steps in the sequence of root canal obturation are:

- choosing a technique and timing the obturation
- selecting master cones
- canal drying, sealer application
- filling the apical portion (lateral and vertical compaction)
- completing the fill
- assessing the quality of the fill

The root canal system should be assessed before choosing an obturation technique. In the presence of open apices or procedural errors such as apical zipping and also for teeth with apices in close proximity to the mandibular canal, there is significant potential for overfills. In order to avoid such mishaps, these cases may be better obturated with cold lateral condensation to avoid overfilling, or in some cases, MTA may be placed as a barrier.

In general, canals should only be filled when there are no symptoms of acute apical periodontitis or an apical abscess, such as significant pain on percussion or not dryable due to secretion into the canal. Gutta-percha cones first should be disinfected by submerging them in an NaOCl solution for about 60 seconds.

In addition to a solid filler such as gutta-percha, a sealer or cement should be used. Most sealers are toxic in the freshly mixed state, but this toxicity is reduced after setting. When in contact with tissues and tissue fluids, zinc oxide eugenol-based sealers are absorbable while resin-based materials typically are not absorbed (30). Some by-products

ENDODONTICS: Colleagues for Excellence

of sealers may adversely affect and delay healing. Therefore, sealers should not be routinely extruded into the periradicular tissues.

The appropriate amount of sealer is then deposited into the canal system. This may be done using a lentulo spiral, a K-file or the master cones themselves; each method is acceptable, provided that an appropriate amount of sealer is deposited. If the master cones are the carrier for the sealer, they should be removed and inspected for a complete coating with sealer and then replaced in the canal.

The master cones are placed close to working length using a slight pumping motion to allow trapped air and the excess sealer to flow in a coronal direction. The marking on the cone should be close to the coronal reference point for working length determination. For lateral compaction, a preselected finger spreader is then slowly inserted alongside the master cone to the marked length and held with measured apical pressure for about 10 seconds. During this procedure, the master cone is pushed laterally and vertically as the clinician feels the compression of the gutta-percha. Rotation of the spreader around its axis will disengage it from the gutta-percha mass and facilitate removal from the canal.

The space created by the spreader is filled by inserting a small, lightly sealer-coated accessory gutta-percha cone. Using auxiliary cones larger than the taper of the spreader will produce voids or sealer pools in the filling and should be avoided. The procedure is repeated by inserting several gutta-percha cones until the entire canal is filled.

For vertical compaction, electrically heated pluggers are used to melt a master cone fitted to length. Tapered gutta-percha cones optimize the hydraulic forces that arise during compaction of softened gutta-percha with pluggers of a similar taper. After fitting the master cone as before, different hand pluggers and heated pluggers are placed into the root canal to verify a fit to within 5 to 7 mm of the apical constriction.

For both lateral and vertical compaction the gutta-percha mass in each canal should end about 1 mm below the pulpal floor, leaving a small dimple. In cases where placement of a post is planned, gutta-percha is confined to the apical 5 mm (31). All root canals that do not receive a post may be protected with an orifice barrier (Figure 3) to protect from leakage prior to placement of a definitive restoration (32). This has been shown to promote healing of apical periodontitis (33). Materials that are suitable for such a barrier include light-curing glass ionomers, flowable composites or fissure sealants. In order to facilitate retreatment if necessary, such a barrier should be thin so that the gutta-percha fill is just visible.

Radiographic Appearance of Filled Root Canal Systems

Prepared and filled canals should demonstrate a homogenous radiopaque appearance, free of voids and filled to working length. The fill should approximate canal walls and extend as much as possible into canal irregularities such as an isthmus or a c-shaped canal system. This is difficult to achieve clinically and frequently requires the clinician to use a thermoplastic obturation technique. This complicated procedure may benefit from the use of the dental operating microscope.

Other anatomical spaces that may be filled include accessory canals that are most common in the apical root third (Fig. 3, mesial and distal root) but may be found in other locations such as the furcation. It has been well established that accessory anatomy may contribute to periapical periodontitis (34) but clinical experience suggests the role of accessory anatomy in causing bone resorption is comparatively small. Indeed it appears that filling accessory canals is not predictable and not *per se* a prerequisite for success (35).

In order to avoid overextension of root filling material into the periapical tissue, specifically in the mandibular canal, it is recommended to accurately determine working length to prevent destruction of the apical constriction. For infected root canal systems, it seems that the best healing results are achieved when the working length is slightly short of the tip of the root, as visible on a radiograph (25, 36).

Determination of apical canal anatomy is often difficult. It may be appropriate for second mandibular molars that are in close proximity to the mandibular canal to be referred to a specialist. Overfills are not only an impediment to healing but in the worst case can be associated with permanent nerve damage. In general, undesirable and uncorrectable outcomes of root canal treatment, identifiable on the final radiograph, include:

- excessive dentin removal during access and instrumentation
- preparation errors such as perforation, ledge formation and apical zipping
- presence of an instrument fragment in not fully disinfected canals
- obturation material overfill and overextension

Canal Preparation and Obturation: An Updated View of the Two Pillars of Nonsurgical Endodontics

Each of these outcomes must be documented and the patient notified as they may reduce the likelihood of a successful outcome. In cases such as par- or dysesthesia after an overfill, immediate referral to a surgeon is indicated.

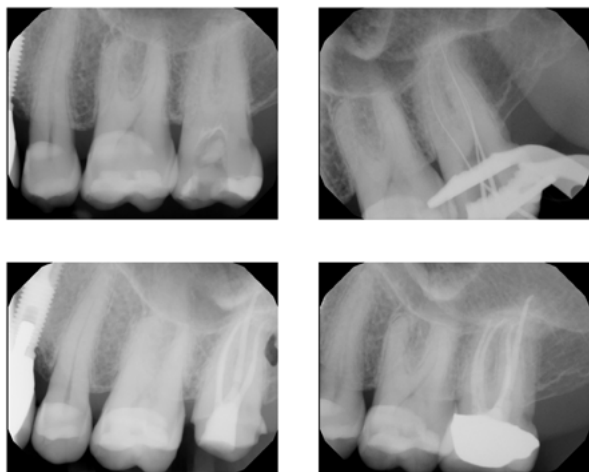


Fig. 4. Root canal treatment of tooth #15 with four canals, diagnosed with irreversible pulpitis and acute apical periodontitis. The tooth was restored with a crown immediately after finalizing the root canal treatment. (Case courtesy of Dr. Reza Hamid)

Summary and Conclusions

Root canal preparation with contemporary instruments is a predictable procedure in most cases for a well-trained clinician following established guidelines. Cases with a recognized high degree of difficulty are best referred to an endodontist. While many cases can be treated successfully in routine practice, the additional training, expertise and technology of endodontists is necessary in cases that are beyond the typical spectrum. The best long-term outcomes are obtained when a correctly planned final restoration is placed as soon as possible after root canal treatment is completed (Figure 4). Root canals may be filled through various methods, typically using a combination of a cement and a solid filling material such as gutta-percha. The specific obturation material used appears to have a smaller role on outcomes. Overfills, particularly into the area of the inferior alveolar nerve, have the potential to permanently harm a patient. The absence of gross errors that are associated with persistent presence of bacterial infection and excessive dentin removal during access and canal preparation have the greatest impact on outcomes.

References

1. Karabucak B, Bunes A, Chehoud C, Kohli MR, Setzer F. Prevalence of apical periodontitis in endodontically treated premolars and molars with untreated canal: A cone-beam computed tomography study. *J Endod* 2016;42:538-41.
2. Walia H, Brantley WA, Gerstein H. An initial investigation of the bending and torsional properties of nitinol root canal files. *J Endod* 1988;14:346-51.
3. Gluskin AH, Peters CI, Peters OA. Minimally invasive endodontics: challenging prevailing paradigms. *Br Dent J* 2014;216:347-53.
4. Thompson SA. An overview of nickel-titanium alloys used in dentistry. *Int Endod J* 2000;33:297-310.
5. Shen Y, Zhou HM, Zheng YF, Peng B, Haapasalo M. Current challenges and concepts of the thermomechanical treatment of nickel-titanium instruments. *J Endod* 2013;39:163-72.
6. Peters OA, Morgental RD, Schulze KA, Paqué F, Kopper PMP, Vier-Pelisser FV. Determining cutting efficiency of nickel-titanium coronal flaring instruments used in lateral action. *Int Endod J* 2013.
7. Pettiette MT, Metzger Z, Phillips C, Trope M. Endodontic complications of root canal therapy performed by dental students with stainless-steel K-files and nickel-titanium hand files. *J Endod* 1999;25:230-34.
8. Paque F, Barbakow F, Peters OA. Root canal preparation with Endo-Eze AET: changes in root canal shape assessed by micro-computed tomography. *Int Endod J* 2005;38:456-64.
9. Schäfer E, Lau R. Comparison of cutting efficiency and instrumentation of curved canals with Nickel-Titanium and stainless-steel instruments. *J Endod* 1999;25:427-30.
10. Ruddle C. The ProTaper technique. *Endod Topics* 2005;10:187-90.
11. Berutti E, Chiandussi G, Gaviglio I, Ibba A. Comparative analysis of torsional and bending stresses in two mathematical models of nickel-titanium rotary instruments: ProTaper versus ProFile. *J Endod* 2003;29:15-9.
12. Li UM, Lee BS, Shih CT, Lan WH, Lin CP. Cyclic fatigue of endodontic nickel titanium rotary instruments: static and dynamic tests. *J Endod* 2002;28:448-51.
13. Yared GM, Bou Dagher FE, Machtou P. Influence of rotational speed, torque and operator's proficiency on ProFile failures. *Int Endod J* 2001;34:47-53.
14. Cheung GS, Shen Y, Darvell BW. Does electropolishing improve the low-cycle fatigue behavior of a nickel-titanium rotary instrument in hypochlorite? *J Endod* 2007;31:1217-21.
15. Herold KS, Johnson BR, Wenckus CS. A scanning electron microscopy evaluation of microfractures, deformation and separation in EndoSequence and Profile Nickel-Titanium rotary files using an extracted molar tooth model. *J Endod* 2007;33:712-4.
16. Peters OA, Peters CI, Schönenberger K, Barbakow F. ProTaper rotary root canal preparation: assessment of torque and force in relation to canal anatomy. *Int Endod J* 2003;36:93-9.
17. Boessler C, Peters OA, Zehnder M. Impact of lubricant parameter on rotary instrument torque and force. *J Endod* 2007;33:280-3.
18. Sonntag D, Peters OA. Effect of prion decontamination protocols on Nickel-Titanium rotary surfaces. *J Endod* 2007;33.
19. Fonzar F, Fonzar A, Buttolo P, Worthington HV, Esposito M. The prognosis of root canal therapy: a 10-year retrospective cohort study on 411 patients with 1175 endodontically treated teeth. *Eur J Oral Implantol* 2009;2:201-8.
20. Landys Boren D, Jonasson P, Kvist T. Long-term survival of endodontically treated teeth at a public dental specialist clinic. *J Endod* 2015;41:176-81.
21. Ng YL, Mann V, Gulabivala K. A prospective study of the factors affecting outcomes of non-surgical root canal treatment: part 2: tooth survival. *Int Endod J* 2011;44:610-25.
22. Pettiette MT, Delano EO, Trope M. Evaluation of success rate of endodontic treatment performed by students with stainless-steel K-files and nickel-titanium hand files. *J Endod* 2001;27:124-7.
23. Peters OA, Barbakow F, Peters CI. An analysis of endodontic treatment with three nickel-titanium rotary root canal preparation techniques. *Int Endod J* 2004;37:849-59.
24. Li GH, Niu LN, Zhang W, Olsen M, De-Deus G, Eid AA, et al. Ability of new obturation materials to improve the seal of the root canal system: a review. *Acta Biomater* 2014;10:1050-63.
25. Ng Y-L, Mann V, Gulabivala K. A prospective study of the factors affecting outcomes of nonsurgical root canal treatment: part 1: periapical health. *Int Endod J* 2011;44:583-609.
26. Candeiro GT, Correia F, Duarte MA, Ribeiro-Siqueira DC, Gavini G. Evaluation of radiopacity, pH, release of calcium ions, and flow of a bioceramic root canal sealer. *J Endod* 2012;38:842-5.
27. Willershausen I, Wolf T, Kasaj A, Weyer V, Willershausen B, Marroquin BB. Influence of a bioceramic root end material and mineral trioxide aggregates on fibroblasts and osteoblasts. *Arch Oral Biol* 2013;58:1232-7.

28. Waltimo TM, Boiesen J, Eriksen HM, Orstavik D. Clinical performance of 3 endodontic sealers. *Oral Surg Oral Med Oral Pathol Oral Radiol Endod* 2001;92:89-92.

29. Li GH, Niu LN, Selem LC, Eid AA, Bergeron BE, Chen JH, et al. Quality of obturation achieved by an endodontic core-carrier system with crosslinked gutta-percha carrier in single-rooted canals. *J Dent* 2014;42:1124-34.

30. Ricucci D, Rocas IN, Alves FR, Loghin S, Siqueira JF, Jr. Apically extruded sealers: fate and influence on treatment outcome. *J Endod* 2016;42:243-9.

31. Abramovitz L, Lev R, Fuss Z, Metzger Z. The unpredictability of seal after post space preparation: a fluid transport study. *J Endod* 2001;27:292-5.

32. Wolcott JF, Hicks ML, Himel VT. Evaluation of pigmented intraorifice barriers in endodontically treated teeth. *J Endod* 1999;25:589-92.

33. Yamauchi S, Shipper G, Buttke T, Yamauchi M, Trope M. Effect of orifice plugs on periapical inflammation in dogs. *J Endod* 2006;32:524-6.

34. Nicholls E. Lateral radicular disease due to lateral branching of the root canal. *Oral Surg Oral Med Oral Pathol* 1963;16:839-45.

35. Ricucci D, Siqueira JF, Jr. Fate of the tissue in lateral canals and apical ramifications in response to pathologic conditions and treatment procedures. *J Endod* 2010;36:1-15.

36. Ricucci D, Russo J, Rutberg M, Burleson JA, Spangberg LS. A prospective cohort study of endodontic treatments of 1,369 root canals: results after 5 years. *Oral Surg Oral Med Oral Pathol Oral Radiol Endod* 2011;112:825-42.

The AAE wishes to thank Dr. Ove A. Peters for authoring this issue of the newsletter, as well the following article reviewers: Drs. Mark B. Desrosiers, Steven J. Katz, Linda G. Levin, Avina K. Paranjpe and Patrick E. Taylor.

Exclusive Online Bonus Materials: Canal Preparation and Obturation

This issue of the *Colleagues* newsletter is available online at www.aae.org/colleagues with the following exclusive bonus materials:

- Full-Text Article: Shen Y, Zhou HM, Zheng YF, Peng B, Haapasalo M. Current challenges and concepts of the thermomechanical treatment of nickel-titanium instruments. *J Endod* 2013;39:163-72.
- Full-Text Article: Ricucci D, Siqueira JF, Jr. Fate of the tissue in lateral canals and apical ramifications in response to pathologic conditions and treatment procedures. *J Endod* 2010;36:1-15.
- Full-Text Article: Ng Y-L, Mann V, Gulabivala K. A prospective study of the factors affecting outcomes of nonsurgical root canal treatment: part 1: periapical health. *Int Endod J* 2011;44:583-609.
- Full-Text Article: Ng YL, Mann V, Gulabivala K. A prospective study of the factors affecting outcomes of non-surgical root canal treatment: part 2: tooth survival. *Int Endod J* 2011;44:610-25.



211 E. Chicago Ave., Suite 1100
Chicago, IL 60611-2691

Phone: 800-872-3636 (U.S., Canada, Mexico)
or 312-266-7255

Fax: 866-451-9020 (U.S., Canada, Mexico)
or 312-266-9867

Email:



Earn online CE credit when you enjoy
two articles from *Colleagues for Excellence!*

www.aae.org/LiveLearningCenter



Information in this newsletter is designed to aid dentists. Practitioners must use their best professional judgment, taking into account the needs of each individual patient when making diagnosis/treatment plans. The AAE neither expressly nor implicitly warrants against any negative results associated with the application of this information. If you would like more information, consult your endodontic colleague or contact the AAE.

Are there topics you would like to cover in the future? We want to hear from you! Send your comments and questions to the American Association of Endodontists at the address below, and visit the *Colleagues* online archive at www.aae.org/colleagues for back issues of the newsletter.

© 2016

American Association of Endodontists (AAE),
All Rights Reserved